



# MANSAROVAR DENTAL COLLEGE

Mansarovar Campus, Rani Avanti Bai Marg, Village- HinotiaAalam,

Ward No. 84, Kolar Road, Bhopal (M.P) 462042

Tel: +91-9111777225, 761158888. Website: [www.mansarovardentalcollege.com](http://www.mansarovardentalcollege.com)

<b>Name of the partnering Institution/ Industry/ research lab/ corporate house with contact details</b>	<b>Drishti Diagnostics</b>
<b>Year of Commencement of the MoU/ linkage</b>	<b>2019</b>
<b>Title of the Mou/ Linkage</b>	Memorandum of understanding for Student/ Faculty exchange, training academic and research activities
<b>Duration (From – to )</b>	2019-2024
<b>Start Date</b>	02-01-2019
<b>Completion Date</b>	01-01-2024
<b>List the Actual activities under each MoU/ Linkage</b>	Clinical training, Preventive health care projects



**MEMORANDUM OF UNDERSTANDING**  
**MANSAROVAR DENTAL COLLEGE**  
HOSPITAL AND RESEARCH CENTER, BHOPAL (M.P.)  
& Drishti Diagnostics

Between Mansarovar Dental College Hospital & Research Center Bhopal And  
Drishti Diagnostics

This Memorandum of Understanding (MOU) is made and entered into force on  
2<sup>nd</sup> January 2019 between Mansarovar Dental College Hospital & Research Center  
Bhopal, affiliated to Madhya Pradesh Medical Science University, Jabalpur having  
its campus at Rani Avati Bai Marg, Hinotia Alam, Ward No. 84, Kolar Road, Bhopal  
– 462042 (M.P.), India represented by professor Principal of Mansarovar Dental  
College Hospital & Research Center, Dr. B. Gurudutt Nayak, One Part.

And

Drishti Diagnostics, having its center at G-12, Deendayal Parisar, Near BJP Karyalay  
E-2, Arera Colony, Bhopal represented by Dr. Viplav Joshi, Director Drishti  
Diagnostics, the other part.

  
Dr. B. Gurudutt Nayak  
Principal



Here in after collectively also referred to as "parties" and individually as "party". This effective upon signing and shall remain in effect for a period of Five Years or until termination by either party with 30 days written notice whichever is earlier. This agreement may also be extended/modified at the end of the five year after review and need is felt for extension of the agreement.

This Memorandum of Understanding (MOU) is designed to reflect the understanding between **Mansarovar Dental College Hospital & Research Center Bhopal, affiliated to Madhya Pradesh Medical Science University, Jabalpur** referred herein after the **PARTY OF THE FIRST OF THE FIRST PART** and **DRISHTI DIAGNOSTICS, Bhopal**, referred herein after **PARTY OF THE SECOND PART** providing/coordinating services to the staff and students and/or developing infrastructure facilities.

Following the successful cooperation between the two institutions here by confirm their wish to the Memorandum of Understanding on education, training and research collaborations. Both the parties agree to the development of joint activities to address issues of mutual interest designed to foster and promote collaboration in the field of dental education, training and dental/radiology research and projects training through the following activities to promote dental advancements in the country.

**The parties to this Memorandum have the following common objectives:**

1. To assure right delivery of the quality dental/radiographic services at appropriate time by the parties to the stakeholders.
2. To assure the application of the dental services in a systematic way to have faithful benefits to the stakeholders.
3. To assure always effective and efficient services for welfare and benefit of the stakeholders.

#### **ABOUT US:-**

Mansarovar Dental College Hospital and Research Centre was established in 2007 by Sri Sai Gramotthan Samiti at Ward 84, Kolar Road, Bhopal, Madhya Pradesh. The College has an intake of 100 seats in the BDS course and 11 Seats in MDS course across Four Disciplines namely Prosthodontics, Orthodontics, Periodontics, Conservative and Endodontics. Mansarovar Dental College offers a unique opportunity for students to involve in various Research and Development projects in association with various external organizations, in our In house research center and our other associated institutions Run by the Society. Mansarovar Dental College has a fully functional Dental Hospital with State of the art facilities like more than 250 branded dental chairs, OPG, Dental X-Ray, Ceramic Furnace, Induction Casting machines, etc. Regular community camps and the placement of the college in municipal boundaries ensures good OPD which results in ample opportunities for students to do their hands on Practice work.

Drishti Diagnostics is equipped with leading edge technology and has been offering a wide range of radiological and pathology service since 15 Aug 2018 with





a vision to give health care services in the communities. The company has on its panel a good number of fully qualified full time radiologists, pathologists, technologist and support staff.

This MEMORANDUM OF UNDERSTANDING (MOU) witnesses as follows:

**1. Scope : Area and Method of Cooperation –**

The area of co-operation includes any programs offered by either of the participating parties determined to be desirable and feasible for developing co-operative relationships. The methods of co-operation includes subject to availability of funds and the approval of each party, research, training and academic activities or programs such as:

1. Joint research projects and publications, including the work by undergraduate, postgraduate and post doctoral students at partner institutions.
2. Faculty and student exchange.
3. Participation in and co hosting joint workshops, seminars, symposium, meetings and webinars.
4. Visits of faculty, professional staff and dental students (UG/PG/Post doctoral)
5. Collaboration in other areas that foster research training and educational co-operation.

Terms and financial issues shall be discussed and agreed upon in writing by both parties prior to initiation of a particular program or activity. All terms shall be negotiated on a mutual basis and documented in a program or project agreement. Such joint programs and resulting agreements shall specify the specific responsibilities and obligation of each party.

**2. Intellectual property:**

Procedures for handling of intellectual property rights that may arise during the course of this collaboration shall be outlined in a separate document. All terms shall be negotiated on a mutual basis prior to the start of collaborative project in questions and in accordance with the policies of each institution.

**3. Principles:**

Implementation of this MOU will be in accordance with the policies on co-operation of the Mansarovar Dental College Hospital & Research Center Bhopal, affiliated to Madhya Pradesh Medical Science University, Jabalpur and relevant policies at the Dristi Diagnostics Bhopal. Participants under this MOU will be selected on the basis of merit without regard to race, national or ethnic origin, color, religion, sex, age, sexual orientation, marital status or physical handicap and will each accept the participants

Dr. B. Gurudatt Naya,  
Principal  
Mansarovar Dental College  
Bhopal



7. This MOU shall not create any legal obligations on either party and a separate agreement shall be entered into between the parties of this MOU in respect of execution of the work agreed under this MOU.
8. Service audit and program review function shall be performed jointly when appropriate. Both the parties mutually agree not to make use of the names of the other party in any public information without permission of the concerned party.
9. The above MOU is valid for five years from the date of signing.

Mansarovar Dental College Hospital & Research Center Bhopal, affiliated to Madhya Pradesh Medical Science University, Jabalpur and Drishti Diagnostics Bhopal, here by agree to all of the above and enter into a joint agreement until such time that either party shall amend or review the said agreement in writing.

In witness where of the parties here to cause their authorized representatives to sign this MOU on the day month and year mentioned here in belowa.

Signed at Mansarovar Dental College Hospital & Research Center Bhopal, Madhya Pradesh 462042 on 2<sup>nd</sup> January 2019 in two originals in English language one for each party.

Signature :

Name : DR. B. Gurudutt Nayak

Designation : Principal

Seal : **Dr. B. Gurudutt Nayak**

Principal  
Mansarovar Dental College  
BHOPAL



Signature:

Name:

Designation:

Seal:

**DRISHTI DIAGNOSTICS**  
MP-64366-RF-XR-001

Witness: Anup chandravanshi

Signature:

Designation:

Seal :

Witness:

Signature:

Designation:

Seal :

**IDENTIFIED BY ME**  
SIGNATURE   
NAME   
ADDRESS

**ATTESTED**

**M.A. KHAN**  
NOTARY BHOP  
M P (INDIA)

**02 JAN 2019**



# DrishTi Diagnostics

**CBCT | OPG | X-RAY | PATHOLOGY**

G-12, Daandayal Parisar, Near BJP Karyalay, E-2, Arera Colony, Bhopal

Ph.: 0755-4936400, M.: 9926566400

**TIMING :** Monday to Saturday : 10:00 am to 09:00 pm

Sunday : 11:00 am to 02:00 pm

Patient Name : Sauena Age/Sex : 64/M

Referred By Dr. Jay Mantora

Provisional D/Notes : Partially edentulous C 24, 25

## FACILITY AVAILABLE

2D RADIOLOGY	3D RADIOLOGY (CBCT)
<ul style="list-style-type: none"> <li>• OPG</li> <li>• OPG With Analysis</li> <li>• Lateral Cephalogram</li> <li>• Lateral Cephalogram With Analysis</li> <li>• PA/AP View</li> <li>• PNS View</li> <li>• Submentovertex</li> <li>• TMJ</li> <li>• TMJ With Analysis</li> <li>• Bite Wing</li> <li>• Orthopantomogram</li> </ul>	<div> <div> <ul style="list-style-type: none"> <li>• CBCT</li> <li>• Full Mouth (Both Maxilla &amp; Mandible)</li> <li>• Single Jaw (Maxilla / Mandible)</li> <li>• Single Quadrant (UR / UL / LR / LL)</li> <li>• TMJ Analysis</li> <li>• Implant Analysis</li> <li>• Impacted Tooth</li> <li>• Endo Scan</li> </ul> </div> <div> <ul style="list-style-type: none"> <li>• Periapical</li> <li>• ENT Analysis</li> <li>• Maxillary Sinus</li> <li>• Paranasal Sinus</li> <li>• Cyst and Tumors</li> <li>• Single Tooth</li> <li>• Others</li> </ul> </div> </div>
General Pathology	Histopathology (Biopsy)

  
Dr. B. Gurudatt Nayak  
Principal

Mansarovar Dental College

# Drish*i* Diagnostics

**CBCT | OPG | X-RAY | PATHOLOGY**

G-12, Daendayal Parisar, Near BJP Karyalay, E-2, Arera Colony, Bhopal  
Ph.: 0755-4936400, M.: 9926566400

**TIMING** : Monday to Saturday : 10:00 am to 09:00 pm  
Sunday : 11:00 am to 02:00 pm

Patient Name : Reha Shukla Age/Sex : 37/F  
Referred By Dr. Anshul Gupta  
Provisional D/Notes Partially edentulous  
E 36, 37

## FACILITY AVAILABLE

2D RADIOLOGY	3D RADIOLOGY (CBCT)	
<ul style="list-style-type: none"> <li>• OPG</li> <li>• OPG With Analysis</li> <li>• Lateral Cephalogram</li> <li>• Lateral Cephalogram With Analysis</li> <li>• PAJAP View</li> <li>• PNS View</li> <li>• Submentovertex</li> <li>• TMJ</li> <li>• TMJ With Analysis</li> <li>• Bite Wing</li> <li>• Orthopantomogram</li> </ul>	<ul style="list-style-type: none"> <li>• CBCT</li> <li>• Full Mouth (Both Maxilla &amp; Mandible)</li> <li>• Single Jaw (Maxilla / Mandible)</li> <li>• Single Quadrant (UR / UL / LR / LL)</li> <li>• TMJ Analysis</li> <li>• Implant Analysis</li> <li>• Impacted Tooth</li> <li>• Endo Scan</li> </ul>	<ul style="list-style-type: none"> <li>• Perioscan</li> <li>• ENT Analysis</li> <li>• Maxillary Sinus</li> <li>• Paranasal Sinus</li> <li>• Cyst and Tumors</li> <li>• Single Tooth</li> <li>• Others</li> </ul>
General Pathology	Histopathology (Biopsy)	

*Bow*

**Dr. B. Gurudatt Nayak**  
Principal  
Mansarovar Dental College  
BHOPAL



# DrishTi Diagnostics

**ESTABLISHED IN 2016**


Oral & Deendayal Parasar, Near BJP Karyalay, E-2, Arera Colony, Bhopal  
Ph: 0755-4938400, M: 9926538400

**TIMING :** Monday to Saturday : 10:00 am to 09:00 pm  
Sunday : 11:00 am to 02:00 pm

Patient Name: Anubha Gautham Age Sex: 40/F  
Referred By Dr. Renny K Ninan  
Provisional Diagnosis partially edentulous E 14.

## FACILITY AVAILABLE

2D RADIOLOGY	3D RADIOLOGY / CBCT
<ul style="list-style-type: none"> <li>• OPG</li> <li>• OPG With Analysis</li> <li>• Lateral Cephalogram</li> <li>• Lateral Cephalogram With Analysis</li> <li>• PA Ax View</li> <li>• PNS View</li> <li>• Elongation View</li> <li>• TMJ</li> <li>• TMJ Axis Analysis</li> <li>• Site Imaging</li> <li>• Orthopantomogram</li> </ul>	<ul style="list-style-type: none"> <li>• CBCT</li> <li>• Full Mouth (Both Maxilla &amp; Mandible)</li> <li>• Single Jaw (Maxilla / Mandible)</li> <li>• Single Quadrant (UR / UL / LR / LL)</li> <li>• TMJ Analysis</li> <li>• Implant Analysis</li> <li>• Impacted Tooth</li> <li>• Endo Scan</li> <li>• Panoramic</li> <li>• BVT Analysis</li> <li>• Maxillary Sinus</li> <li>• Paranasal Sinus</li> <li>• Cyst and Tumors</li> <li>• Single Tooth</li> <li>• Others</li> </ul>
General Pathology	Histopathology (Biopsy)

  
**Dr. B. Gurudatt Nayak**  
Principal  
Mansarovar Dental College  
Bhopal



# DrishTi Diagnostics

**CBCT | OPG | X-RAY | PATHOLOGY**

G-12, Deendayal Parisar, Near BJP Karyalay, E-2, Arera Colony, Bhopal  
Ph.: 0755-4936400, M.: 9926566400

**TIMING :** Monday to Saturday : 10:00 am to 09:00 pm  
Sunday : 11:00 am to 02:00 pm

Patient Name : Silpa Age/Sex: 26/F  
Referred By Dr. Jeevan Krishna  
Provisional D/Notes partially edentulous ~ 12

## FACILITY AVAILABLE

2D RADIOLOGY	3D RADIOLOGY (CBCT)
<ul style="list-style-type: none"> <li>• OPG</li> <li>• OPG With Analysis</li> <li>• Lateral Cephalogram</li> <li>• Lateral Cephalogram With Analysis</li> <li>• PA/AP View</li> <li>• PNS View</li> <li>• Submentovertex</li> <li>• TMJ</li> <li>• TMJ With Analysis</li> <li>• Bite Wing</li> <li>• Orthopantomogram</li> </ul>	<div> <div>CBCT</div> <ul style="list-style-type: none"> <li>• Full Mouth (Both Maxilla &amp; Mandible)</li> <li>• Single Jaw (Maxilla / Mandible)</li> <li>• Single Quadrant (UR / UL / LR / LL)</li> <li>• TMJ Analysis</li> <li>• Implant Analysis</li> <li>• Impacted Tooth</li> <li>• Endo Scan</li> </ul> </div> <div> <ul style="list-style-type: none"> <li>• Periapical</li> <li>• ENT Analysis</li> <li>• Maxillary Sinus</li> <li>• Paranasal Sinus</li> <li>• Cyst and Tumors</li> <li>• Single Tooth</li> <li>• Others</li> </ul> </div>
General Pathology	Histopathology (Biopsy)

*Dr. B. Gurudatt Nayak*  
Principal  
Mansarovar Dental College  
BHOPEL

# DrishTi Diagnostics

**CBCT | OPG | X-RAY | PATHOLOGY**


G-12, Deendayal Parisar, Near BJP Karyalay, E-2, Arera Colony, Bhopal  
Ph.: 0755-4936400, M.: 9926566400

**TIMING :** Monday to Saturday : 10:00 am to 09:00 pm  
Sunday : 11:00 am to 02:00 pm

Patient Name : Sudha Biliya Age Sex 56 / F  
Referred By Dr. Shubhendra Pandey  
Provisional D/Notes Partially dentulous 235

## FACILITY AVAILABLE

2D RADIOLOGY	3D RADIOLOGY (CBCT)
<ul style="list-style-type: none"> <li>• OPG</li> <li>• OPG With Analysis</li> <li>• Lateral Cephalogram</li> <li>• Lateral Cephalogram With Analysis</li> <li>• PA/AP View</li> <li>• PNS View</li> <li>• Submentovertex</li> <li>• TMJ</li> <li>• TMJ With Analysis</li> <li>• Site Wing</li> <li>• Orthopantomogram</li> </ul>	<div> <div> <b>CBCT</b> <ul style="list-style-type: none"> <li>• Full Mouth (Both Maxilla &amp; Mandible)</li> <li>• Single Jaw (Maxilla / Mandible)</li> <li>• Single Quadrant (UR / UL / LR / LL)</li> <li>• TMJ Analysis</li> <li>• Implant Analysis</li> <li>• Impacted Tooth</li> <li>• Endo Scan</li> </ul> </div> <div> <ul style="list-style-type: none"> <li>• Perioscan</li> <li>• ENT Analysis</li> <li>• Maxillary Sinus</li> <li>• Paranasal Sinus</li> <li>• Cyst and Tumors</li> <li>• Single Tooth</li> <li>• Others</li> </ul> </div> </div>
General Pathology	Histopathology (Biopsy)

  
**Dr. B. Gurudatt Nayek**  
Principal  
Mansarovar Dental College  
BHOPAL



# Drish*i* Diagnostics

**CBCT | OPG | X-RAY | PATHOLOGY**

G-12, Deendayal Parisar, Near BJP Karyalay, E-2, Arera Colony, Bhopal  
Ph.: 0755-4936400, M.: 9926566400

**TIMING :** Monday to Saturday : 10:00 am to 09:00 pm  
Sunday : 11:00 am to 02:00 pm

Patient Name : Rita Devi Age/Sex 50/F  
Referred By Dr. Jeffery Teel  
Provisional D/Notes Mid-medial canal with  
36.

## FACILITY AVAILABLE

2D RADIOLOGY	3D RADIOLOGY (CBCT)		
<ul style="list-style-type: none"> <li>• OPG</li> <li>• OPG With Analysis</li> <li>• Lateral Cephalogram</li> <li>• Lateral Cephalogram With Analysis</li> <li>• PA/AP View</li> <li>• PNS View</li> <li>• Submentovertex</li> <li>• TMJ</li> <li>• TMJ With Analysis</li> <li>• Bite Wing</li> <li>• Orthopantomogram</li> </ul>	<table> <tr> <td> <b>CBCT</b> <ul style="list-style-type: none"> <li>• Full Mouth (Both Maxilla &amp; Mandible)</li> <li>• Single Jaw (Maxilla / Mandible)</li> <li>• Single Quadrant (UR / UL / LR / LL)</li> <li>• TMJ Analysis</li> <li>• Implant Analysis</li> <li>• Impacted Tooth</li> <li>• Endo Scan</li> </ul> </td><td> <ul style="list-style-type: none"> <li>• Perioscan</li> <li>• ENT Analysis</li> <li>• Maxillary Sinus</li> <li>• Paranasal Sinus</li> <li>• Cyst and Tumors</li> <li>• Single Tooth</li> <li>• Others</li> </ul> </td></tr> </table>	<b>CBCT</b> <ul style="list-style-type: none"> <li>• Full Mouth (Both Maxilla &amp; Mandible)</li> <li>• Single Jaw (Maxilla / Mandible)</li> <li>• Single Quadrant (UR / UL / LR / LL)</li> <li>• TMJ Analysis</li> <li>• Implant Analysis</li> <li>• Impacted Tooth</li> <li>• Endo Scan</li> </ul>	<ul style="list-style-type: none"> <li>• Perioscan</li> <li>• ENT Analysis</li> <li>• Maxillary Sinus</li> <li>• Paranasal Sinus</li> <li>• Cyst and Tumors</li> <li>• Single Tooth</li> <li>• Others</li> </ul>
<b>CBCT</b> <ul style="list-style-type: none"> <li>• Full Mouth (Both Maxilla &amp; Mandible)</li> <li>• Single Jaw (Maxilla / Mandible)</li> <li>• Single Quadrant (UR / UL / LR / LL)</li> <li>• TMJ Analysis</li> <li>• Implant Analysis</li> <li>• Impacted Tooth</li> <li>• Endo Scan</li> </ul>	<ul style="list-style-type: none"> <li>• Perioscan</li> <li>• ENT Analysis</li> <li>• Maxillary Sinus</li> <li>• Paranasal Sinus</li> <li>• Cyst and Tumors</li> <li>• Single Tooth</li> <li>• Others</li> </ul>		
General Pathology	Histopathology (Biopsy)		

  
**Dr. B. Gurudatt Nayak**  
Principal  
Mansarovar Dental College  
BHOPAL

# Drish*i* Diagnostics

**CBCT | OPG | X-RAY | PATHOLOGY**


G-12, Deendayal Parisar, Near BJP Karyalay, E-2, Arera Colony, Bhopal  
Ph.: 0755-4936400, M.: 9926566400

**TIMING :** Monday to Saturday : 10:00 am to 09:00 pm  
Sunday : 11:00 am to 02:00 pm

Patient Name : Hemlata Age/Sex 50/F  
Referred By Dr. Rakshina Siddiqui  
Provisional D/Notes 2 roots & 2 root canals 2/16

## FACILITY AVAILABLE

2D RADIOLOGY	3D RADIOLOGY (CBCT)		
<ul style="list-style-type: none"> <li>• OPG</li> <li>• OPG With Analysis</li> <li>• Lateral Cephalogram</li> <li>• Lateral Cephalogram With Analysis</li> <li>• PA/AP View</li> <li>• PNS View</li> <li>• Submentovertex</li> <li>• TMJ</li> <li>• TMJ With Analysis</li> <li>• Bite Wing</li> <li>• Orthopantomogram</li> </ul>	<table> <tr> <td> <b>CBCT</b> <ul style="list-style-type: none"> <li>• Full Mouth (Both Maxilla &amp; Mandible)</li> <li>• Single Jaw (Maxilla / Mandible)</li> <li>• Single Quadrant (UR / UL / LR / LL)</li> <li>• TMJ Analysis</li> <li>• Implant Analysis</li> <li>• Impacted Tooth</li> <li>• Endo Scan</li> </ul> </td><td> <ul style="list-style-type: none"> <li>• Perioscan</li> <li>• ENT Analysis</li> <li>• Maxillary Sinus</li> <li>• Paranasal Sinus</li> <li>• Cyst and Tumors</li> <li>• Single Tooth</li> <li>• Others</li> </ul> </td></tr> </table>	<b>CBCT</b> <ul style="list-style-type: none"> <li>• Full Mouth (Both Maxilla &amp; Mandible)</li> <li>• Single Jaw (Maxilla / Mandible)</li> <li>• Single Quadrant (UR / UL / LR / LL)</li> <li>• TMJ Analysis</li> <li>• Implant Analysis</li> <li>• Impacted Tooth</li> <li>• Endo Scan</li> </ul>	<ul style="list-style-type: none"> <li>• Perioscan</li> <li>• ENT Analysis</li> <li>• Maxillary Sinus</li> <li>• Paranasal Sinus</li> <li>• Cyst and Tumors</li> <li>• Single Tooth</li> <li>• Others</li> </ul>
<b>CBCT</b> <ul style="list-style-type: none"> <li>• Full Mouth (Both Maxilla &amp; Mandible)</li> <li>• Single Jaw (Maxilla / Mandible)</li> <li>• Single Quadrant (UR / UL / LR / LL)</li> <li>• TMJ Analysis</li> <li>• Implant Analysis</li> <li>• Impacted Tooth</li> <li>• Endo Scan</li> </ul>	<ul style="list-style-type: none"> <li>• Perioscan</li> <li>• ENT Analysis</li> <li>• Maxillary Sinus</li> <li>• Paranasal Sinus</li> <li>• Cyst and Tumors</li> <li>• Single Tooth</li> <li>• Others</li> </ul>		
General Pathology	Histopathology (Biopsy)		

  
**Dr. B. Gurudatt Nayak**  
Principal  
Mansarovar Dental College  
BHOPAL



# Drish*i* Diagnostics

**CBCT | OPG | X-RAY | PATHOLOGY**


G-12, Deendayal Parisar, Near BJP Karyalay, E-2, Arera Colony, Bhopal  
Ph.: 0755-4936400, M.: 9926566400

**TIMING :** Monday to Saturday : 10:00 am to 09:00 pm  
Sunday : 11:00 am to 02:00 pm

Patient Name : Kushilal Sabri Age/Sex 42/M  
Referred By Dr. Abiraj Jain  
Provisional D/Notes Urd distal canal = 46

## FACILITY AVAILABLE

2D RADIOLOGY	3D RADIOLOGY (CBCT)		
<ul style="list-style-type: none"> <li>• OPG</li> <li>• OPG With Analysis</li> <li>• Lateral Cephalogram</li> <li>• Lateral Cephalogram With Analysis</li> <li>• PA/AP View</li> <li>• PNS View</li> <li>• Submentovertex</li> <li>• TMJ</li> <li>• TMJ With Analysis</li> <li>• Bite Wing</li> <li>• Orthopantomogram</li> </ul>	<table> <tr> <td> <b>CBCT</b> <ul style="list-style-type: none"> <li>• Full Mouth (Both Maxilla &amp; Mandible)</li> <li>• Single Jaw (Maxilla / Mandible)</li> <li>• Single Quadrant (UR / UL / LR / LL)</li> <li>• TMJ Analysis</li> <li>• Implant Analysis</li> <li>• Impacted Tooth</li> <li>• Endo Scan</li> </ul> </td><td> <ul style="list-style-type: none"> <li>• Perioscan</li> <li>• ENT Analysis</li> <li>• Maxillary Sinus</li> <li>• Paranasal Sinus</li> <li>• Cyst and Tumors</li> <li>• Single Tooth</li> <li>• Others</li> </ul> </td></tr> </table>	<b>CBCT</b> <ul style="list-style-type: none"> <li>• Full Mouth (Both Maxilla &amp; Mandible)</li> <li>• Single Jaw (Maxilla / Mandible)</li> <li>• Single Quadrant (UR / UL / LR / LL)</li> <li>• TMJ Analysis</li> <li>• Implant Analysis</li> <li>• Impacted Tooth</li> <li>• Endo Scan</li> </ul>	<ul style="list-style-type: none"> <li>• Perioscan</li> <li>• ENT Analysis</li> <li>• Maxillary Sinus</li> <li>• Paranasal Sinus</li> <li>• Cyst and Tumors</li> <li>• Single Tooth</li> <li>• Others</li> </ul>
<b>CBCT</b> <ul style="list-style-type: none"> <li>• Full Mouth (Both Maxilla &amp; Mandible)</li> <li>• Single Jaw (Maxilla / Mandible)</li> <li>• Single Quadrant (UR / UL / LR / LL)</li> <li>• TMJ Analysis</li> <li>• Implant Analysis</li> <li>• Impacted Tooth</li> <li>• Endo Scan</li> </ul>	<ul style="list-style-type: none"> <li>• Perioscan</li> <li>• ENT Analysis</li> <li>• Maxillary Sinus</li> <li>• Paranasal Sinus</li> <li>• Cyst and Tumors</li> <li>• Single Tooth</li> <li>• Others</li> </ul>		
General Pathology	Histopathology (Biopsy)		

  
**Dr. B. Gurudatt Nayak**  
Principal  
Mansarovar Dental College  
BHOPAL

# DrishTi Diagnostics

**CBCT | OPG | X-RAY | PATHOLOGY**

G-12, Deendayal Parisar, Near BJP Karyalay, E-2, Arera Colony, Bhopal  
Ph.: 0755-4936400, M.: 9926566400

**TIMING** : Monday to Saturday : 10:00 am to 09:00 pm  
Sunday : 11:00 am to 02:00 pm

Patient Name : Shalini Jha Age/Sex 28/F  
Referred By Dr. Rajvardhan Shinde  
Provisional D/Notes Supernumerary tooth fused to 47 with additional Buccal & Lingual roots.

## FACILITY AVAILABLE

2D RADIOLOGY	3D RADIOLOGY (CBCT)		
<ul style="list-style-type: none"> <li>• OPG</li> <li>• OPG With Analysis</li> <li>• Lateral Cephalogram</li> <li>• Lateral Cephalogram With Analysis</li> <li>• PA/AP View</li> <li>• PNS View</li> <li>• Submentovertex</li> <li>• TMJ</li> <li>• TMJ With Analysis</li> <li>• Bite Wing</li> <li>• Orthopantomogram</li> </ul>	<table> <tr> <td> <b>CBCT</b> <ul style="list-style-type: none"> <li>• Full Mouth (Both Maxilla &amp; Mandible)</li> <li>• Single Jaw (Maxilla / Mandible)</li> <li>• Single Quadrant (UR / UL / LR / LL)</li> <li>• TMJ Analysis</li> <li>• Implant Analysis</li> <li>• Impacted Tooth</li> <li>• Endo Scan</li> </ul> </td><td> <ul style="list-style-type: none"> <li>• Perioscan</li> <li>• ENT Analysis</li> <li>• Maxillary Sinus</li> <li>• Paranasal Sinus</li> <li>• Cyst and Tumors</li> <li>• Single Tooth</li> <li>• Others</li> </ul> </td></tr> </table>	<b>CBCT</b> <ul style="list-style-type: none"> <li>• Full Mouth (Both Maxilla &amp; Mandible)</li> <li>• Single Jaw (Maxilla / Mandible)</li> <li>• Single Quadrant (UR / UL / LR / LL)</li> <li>• TMJ Analysis</li> <li>• Implant Analysis</li> <li>• Impacted Tooth</li> <li>• Endo Scan</li> </ul>	<ul style="list-style-type: none"> <li>• Perioscan</li> <li>• ENT Analysis</li> <li>• Maxillary Sinus</li> <li>• Paranasal Sinus</li> <li>• Cyst and Tumors</li> <li>• Single Tooth</li> <li>• Others</li> </ul>
<b>CBCT</b> <ul style="list-style-type: none"> <li>• Full Mouth (Both Maxilla &amp; Mandible)</li> <li>• Single Jaw (Maxilla / Mandible)</li> <li>• Single Quadrant (UR / UL / LR / LL)</li> <li>• TMJ Analysis</li> <li>• Implant Analysis</li> <li>• Impacted Tooth</li> <li>• Endo Scan</li> </ul>	<ul style="list-style-type: none"> <li>• Perioscan</li> <li>• ENT Analysis</li> <li>• Maxillary Sinus</li> <li>• Paranasal Sinus</li> <li>• Cyst and Tumors</li> <li>• Single Tooth</li> <li>• Others</li> </ul>		
General Pathology	Histopathology (Biopsy) **		

*[Signature]*  
**Dr. B. Gurudatt Nayak**  
Principal  
Mansarovar Dental College  
BHOPAL



# DrishTi Diagnostics

**CBCT | OPG | X-RAY | PATHOLOGY**

G-12, Deendayal Parisar, Near BJP Karyalay, E-2, Arera Colony, Bhopal  
Ph.: 0755-4936400, M.: 9926566400

**TIMING :** Monday to Saturday : 10:00 am to 09:00 pm  
Sunday : 11:00 am to 02:00 pm

Patient Name : Vansh Rai Age/Sex 14/M  
Referred By Dr. Chinmay Vastak  
Provisional D/Notes 2 roots, 2 root canals - 16

## FACILITY AVAILABLE

2D RADIOLOGY	3D RADIOLOGY (CBCT)		
<ul style="list-style-type: none"> <li>• OPG</li> <li>• OPG With Analysis</li> <li>• Lateral Cephalogram</li> <li>• Lateral Cephalogram With Analysis</li> <li>• PA/AP View</li> <li>• PNS View</li> <li>• Submentovertex</li> <li>• TMJ</li> <li>• TMJ With Analysis</li> <li>• Bite Wing</li> <li>• Orthopantomogram</li> </ul>	<table> <tr> <td> <b>CBCT</b> <ul style="list-style-type: none"> <li>• Full Mouth (Both Maxilla &amp; Mandible)</li> <li>• Single Jaw (Maxilla / Mandible)</li> <li>• Single Quadrant (UR / UL / LR / LL)</li> <li>• TMJ Analysis</li> <li>• Implant Analysis</li> <li>• Impacted Tooth</li> <li>• Endo Scan</li> </ul> </td><td> <ul style="list-style-type: none"> <li>• Perioscan</li> <li>• ENT Analysis</li> <li>• Maxillary Sinus</li> <li>• Paranasal Sinus</li> <li>• Cyst and Tumors</li> <li>• Single Tooth</li> <li>• Others</li> </ul> </td></tr> </table>	<b>CBCT</b> <ul style="list-style-type: none"> <li>• Full Mouth (Both Maxilla &amp; Mandible)</li> <li>• Single Jaw (Maxilla / Mandible)</li> <li>• Single Quadrant (UR / UL / LR / LL)</li> <li>• TMJ Analysis</li> <li>• Implant Analysis</li> <li>• Impacted Tooth</li> <li>• Endo Scan</li> </ul>	<ul style="list-style-type: none"> <li>• Perioscan</li> <li>• ENT Analysis</li> <li>• Maxillary Sinus</li> <li>• Paranasal Sinus</li> <li>• Cyst and Tumors</li> <li>• Single Tooth</li> <li>• Others</li> </ul>
<b>CBCT</b> <ul style="list-style-type: none"> <li>• Full Mouth (Both Maxilla &amp; Mandible)</li> <li>• Single Jaw (Maxilla / Mandible)</li> <li>• Single Quadrant (UR / UL / LR / LL)</li> <li>• TMJ Analysis</li> <li>• Implant Analysis</li> <li>• Impacted Tooth</li> <li>• Endo Scan</li> </ul>	<ul style="list-style-type: none"> <li>• Perioscan</li> <li>• ENT Analysis</li> <li>• Maxillary Sinus</li> <li>• Paranasal Sinus</li> <li>• Cyst and Tumors</li> <li>• Single Tooth</li> <li>• Others</li> </ul>		
General Pathology	Histopathology (Biopsy)		

*[Signature]*  
**Dr. B. Gurudatt Nayak**  
Principal  
Mansarovar Dental College  
BHOPAL

# Drishi Diagnostics

**CBCT | OPG | X-RAY | PATHOLOGY**

G-12, Deendayal Parisar, Near BJP Karyalay, E-2, Arera Colony, Bhopal  
Ph.: 0755-4936400, M.: 9926566400

**TIMING :** Monday to Saturday : 10:00 am to 09:00 pm  
Sunday : 11:00 am to 02:00 pm

Patient Name : Hemant Yadav Age/Sex 21/M  
Referred By Dr. Nishu Singh  
Provisional D/Notes Internal Resorption 2 11, 21

## FACILITY AVAILABLE

2D RADIOLOGY	3D RADIOLOGY (CBCT)		
<ul style="list-style-type: none"> <li>• OPG</li> <li>• OPG With Analysis</li> <li>• Lateral Cephalogram</li> <li>• Lateral Cephalogram With Analysis</li> <li>• PA/AP View</li> <li>• PNS View</li> <li>• Submentovertex</li> <li>• TMJ</li> <li>• TMJ With Analysis</li> <li>• Bite Wing</li> <li>• Orthopantomogram</li> </ul>	<table> <tr> <td> <b>CBCT</b> <ul style="list-style-type: none"> <li>• Full Mouth (Both Maxilla &amp; Mandible)</li> <li>• Single Jaw (Maxilla / Mandible)</li> <li>• Single Quadrant (UR / UL / LR / LL)</li> <li>• TMJ Analysis</li> <li>• Implant Analysis</li> <li>• Impacted Tooth</li> <li>• Endo Scan</li> </ul> </td><td> <ul style="list-style-type: none"> <li>• Perioscan</li> <li>• ENT Analysis</li> <li>• Maxillary Sinus</li> <li>• Paranasal Sinus</li> <li>• Cyst and Tumors</li> <li>• Single Tooth</li> <li>• Others</li> </ul> </td></tr> </table>	<b>CBCT</b> <ul style="list-style-type: none"> <li>• Full Mouth (Both Maxilla &amp; Mandible)</li> <li>• Single Jaw (Maxilla / Mandible)</li> <li>• Single Quadrant (UR / UL / LR / LL)</li> <li>• TMJ Analysis</li> <li>• Implant Analysis</li> <li>• Impacted Tooth</li> <li>• Endo Scan</li> </ul>	<ul style="list-style-type: none"> <li>• Perioscan</li> <li>• ENT Analysis</li> <li>• Maxillary Sinus</li> <li>• Paranasal Sinus</li> <li>• Cyst and Tumors</li> <li>• Single Tooth</li> <li>• Others</li> </ul>
<b>CBCT</b> <ul style="list-style-type: none"> <li>• Full Mouth (Both Maxilla &amp; Mandible)</li> <li>• Single Jaw (Maxilla / Mandible)</li> <li>• Single Quadrant (UR / UL / LR / LL)</li> <li>• TMJ Analysis</li> <li>• Implant Analysis</li> <li>• Impacted Tooth</li> <li>• Endo Scan</li> </ul>	<ul style="list-style-type: none"> <li>• Perioscan</li> <li>• ENT Analysis</li> <li>• Maxillary Sinus</li> <li>• Paranasal Sinus</li> <li>• Cyst and Tumors</li> <li>• Single Tooth</li> <li>• Others</li> </ul>		
General Pathology	Histopathology (Biopsy)		

*Bow*  
**Dr. B. Gurudatt Nayak**  
Principal  
Mansarovar Dental College  
BHOPL



# Drish*i* Diagnostics

**CBCT | OPG | X-RAY | PATHOLOGY**


G-12, Deendayal Parisar, Near BJP Karyalay, E-2, Arera Colony, Bhopal  
Ph.: 0755-4936400, M.: 9926566400

**TIMING** : Monday to Saturday : 10:00 am to 09:00 pm  
Sunday : 11:00 am to 02:00 pm

Patient Name : Tyagant Singh Age/Sex 43/M  
Referred By Dr. Pratiksha Sharma  
Provisional D/Notes Radiiz entomolars with  
Ab.

## FACILITY AVAILABLE

2D RADIOLOGY	3D RADIOLOGY (CBCT)		
<ul style="list-style-type: none"> <li>• OPG</li> <li>• OPG With Analysis</li> <li>• Lateral Cephalogram</li> <li>• Lateral Cephalogram With Analysis</li> <li>• PA/AP View</li> <li>• PNS View</li> <li>• Submentovertex</li> <li>• TMJ</li> <li>• TMJ With Analysis</li> <li>• Bite Wing</li> <li>• Orthopantomogram</li> </ul>	<table> <tr> <td> <b>CBCT</b> <ul style="list-style-type: none"> <li>• Full Mouth (Both Maxilla &amp; Mandible)</li> <li>• Single Jaw (Maxilla / Mandible)</li> <li>• Single Quadrant (UR / UL / LR / LL)</li> <li>• TMJ Analysis</li> <li>• Implant Analysis</li> <li>• Impacted Tooth</li> <li>• Endo Scan</li> </ul> </td><td> <ul style="list-style-type: none"> <li>• Perioscan</li> <li>• ENT Analysis</li> <li>• Maxillary Sinus</li> <li>• Paranasal Sinus</li> <li>• Cyst and Tumors</li> <li>• Single Tooth</li> <li>• Others</li> </ul> </td></tr> </table>	<b>CBCT</b> <ul style="list-style-type: none"> <li>• Full Mouth (Both Maxilla &amp; Mandible)</li> <li>• Single Jaw (Maxilla / Mandible)</li> <li>• Single Quadrant (UR / UL / LR / LL)</li> <li>• TMJ Analysis</li> <li>• Implant Analysis</li> <li>• Impacted Tooth</li> <li>• Endo Scan</li> </ul>	<ul style="list-style-type: none"> <li>• Perioscan</li> <li>• ENT Analysis</li> <li>• Maxillary Sinus</li> <li>• Paranasal Sinus</li> <li>• Cyst and Tumors</li> <li>• Single Tooth</li> <li>• Others</li> </ul>
<b>CBCT</b> <ul style="list-style-type: none"> <li>• Full Mouth (Both Maxilla &amp; Mandible)</li> <li>• Single Jaw (Maxilla / Mandible)</li> <li>• Single Quadrant (UR / UL / LR / LL)</li> <li>• TMJ Analysis</li> <li>• Implant Analysis</li> <li>• Impacted Tooth</li> <li>• Endo Scan</li> </ul>	<ul style="list-style-type: none"> <li>• Perioscan</li> <li>• ENT Analysis</li> <li>• Maxillary Sinus</li> <li>• Paranasal Sinus</li> <li>• Cyst and Tumors</li> <li>• Single Tooth</li> <li>• Others</li> </ul>		
General Pathology	Histopathology (Biopsy)		

  
**Dr. B. Gurudatt Nayak**  
Principal  
Mansarovar Dental College  
BHOPAL

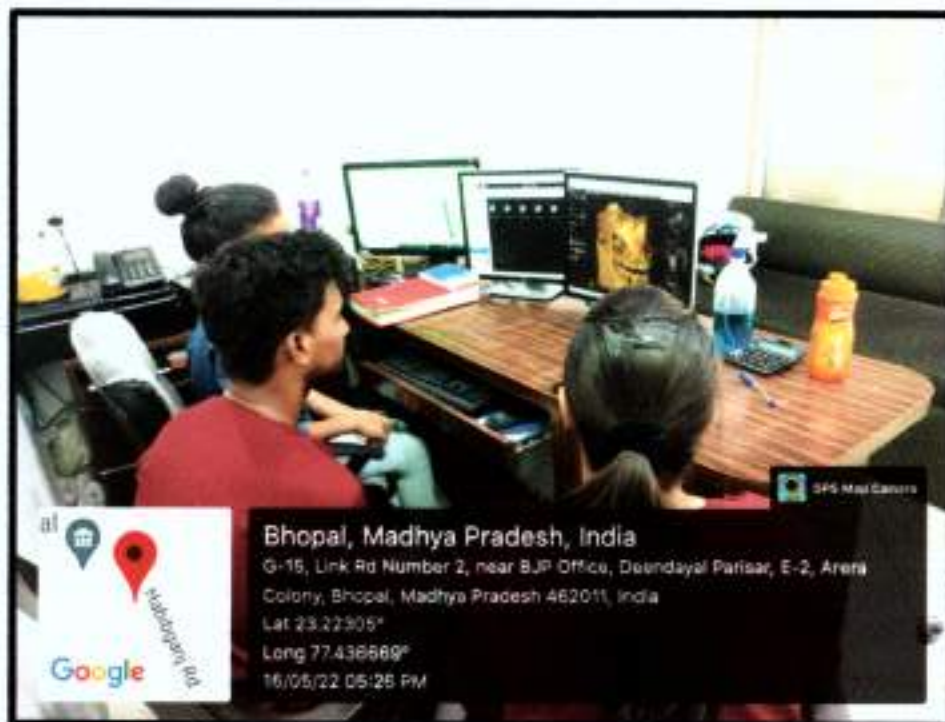
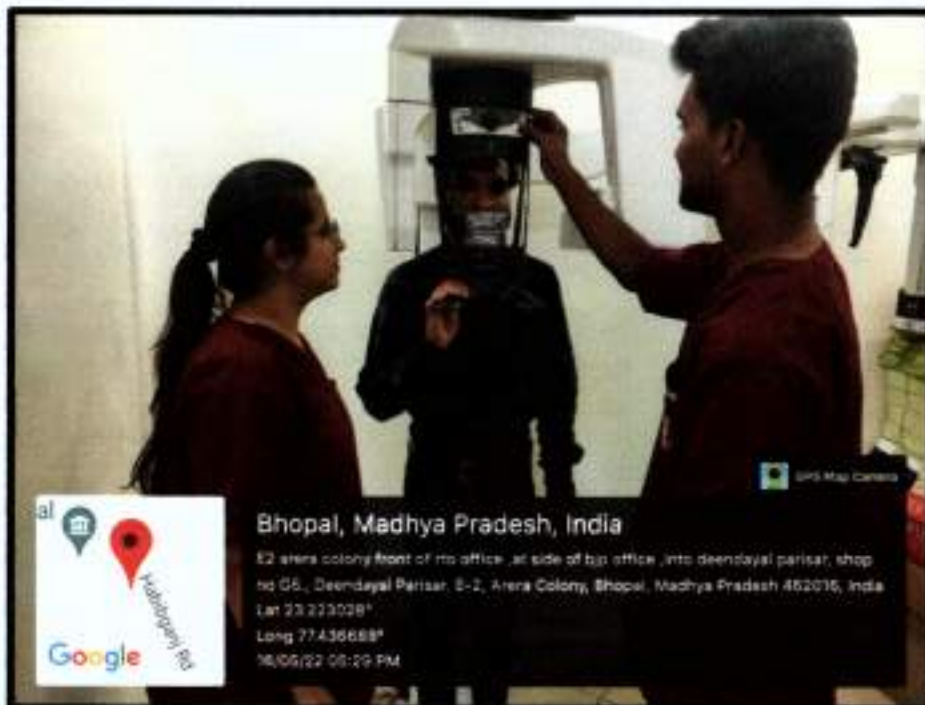
# MANSAROVAR DENTAL COLLEGE

Mansarovar Campus, Rani Avanti Bai Marg, Village- Hinotia Aalam,  
Ward No. 84, Kolar Road, Bhopal (M.P) 462042

Tel: +91-9111777225, 761158888. Website: [www.mansarovardentalcollege.com](http://www.mansarovardentalcollege.com)

## CBCT Demonstration and Training Programme under MOU at Drishti Diagnostics



  
**Dr. B. Gurudatt Nayak**  
Principal  
Mansarovar Dental College  
BHOPAL